

Topical application of vitamin D cream in participants with inflammatory acne due to vitamin D deficiency

Lana Lekić¹, Bojan Pavlović²

¹Faculty of Health Studies, University of Sarajevo, Bosnia and Herzegovina.

²MPT, Faculty of Sport and Physical Education Sarajevo, University of East Sarajevo.

Abstract:

Acne vulgaris (AV) represents a chronic inflammatory condition affecting pilosebaceous units, characterized by a multifactorial etiology. AV can manifest as both inflammatory and non-inflammatory skin lesions. Non-inflammatory acne is termed a comedone, which can be either closed (whiteheads) or open (blackheads). Inflammatory acne encompasses papules, pustules, nodules, and pseudocysts. The most common regions for acne occurrence are the facial region (90%), thoracic area (14%), and dorsal region (60%). In the study involving transdermal application of vitamin D cream (applied twice daily; morning and evening) in subjects with inflammatory acne due to vitamin D deficiency, 33 participants took part, comprising 8 males and 25 females. The age group most affected was 18-25 years (adolescent age), followed by a lesser impact in the 26-30 age group, and the lowest incidence observed in the late 36-45 age group. Among males, facial and thoracic regions were most affected by inflammatory acne (37.5%), while among females, the facial region showed a higher percentage of 54%, and the thoracic area was at 40%, with a minimal impact on the dorsal region (M=25%; F=8%). Reductions in inflammatory acne ranged from 100% to 10%, with substantial improvements noted in the male population, achieving 100% and 80% reduction (100% reduction: facial region 25%, thoracic area 12.5%, 80% reduction: dorsal region 25%). Similarly, the female group, with a larger sample size (25 participants), demonstrated significant reductions (100% reduction: facial region 36%, thoracic area 24%, 80% reduction: dorsal area 4%). Overall, improvements were evident in all participants, with none falling below a 30% reduction, indicating remarkable outcomes after one month of vitamin D cream use. Numerous factors contribute to the onset of inflammatory acne, with this study specifically highlighting vitamin D deficiency in the blood. Other indications include the occurrence of polycystic ovaries and reduced thyroid function in women, heightened stress, and prostate issues in men. Reduced or deficient vitamin D levels may be associated with further immune system suppression, activating the aforementioned factors. This research marks a significant stride in uncovering the manifold health benefits of vitamin D.

Keywords: *acne, vitamin D, participants*

1. Introduction

Vitamin D, along with its metabolites and analogs, constitutes a group of compounds with numerous functions in the body. One of its characteristics is the fat-soluble nature of secosteroids and prohormones. There are two forms of vitamin D: Vitamin D₂ (ergocalciferol) and Vitamin D₃ (cholecalciferol). Its function involves synthesis in the body, specifically in the skin, from endogenous cholesterol (7-dehydrocholesterol) under the influence of UV B (290-315 nm) radiation. It transforms from its prohormone form into the active form of vitamin D, is metabolized in the liver into 25-hydroxyvitamin D (25-OH D),

and further converted in the kidneys into the active form, calcitriol (1,25 (OH)₂ vitamin D) [6].

Moreover, vitamin D is a modulator of Ca and Mg metabolism. It affects both the innate and adaptive immune system through its effects on T and B lymphocytes, dendritic cells, and macrophages. It is associated with systemic inflammatory diseases such as rheumatoid arthritis, inflammatory bowel diseases, systemic lupus erythematosus. Vitamin D also regulates the proliferation and differentiation of keratinocytes and sebocytes, possessing antioxidant and anti-comedogenic properties [3].

In dermatological diseases, it plays a significant role as an immune modulator in atopic dermatitis, psoriasis, alopecia, vitiligo, and acne. Numerous literary works support this theory, and in vitro studies have explored the role of vitamin D in the development of acne. The identification of vitamin D receptors in human sebocytes and modulation of lipid and cytokine production by vitamin D suggest a potential association between vitamin D and the pathophysiology of acne. *Acne vulgaris* (AV) is a common disorder of pilosebaceous follicles that typically affects the skin of the face, neck, upper part of the trunk and back [7]. Acne commonly affects around 85% of adolescents and approximately 30% of adults, known as post-adolescent acne, often occurring in individuals aged 25 years or older, especially women [5].

During adolescence, it most commonly arises due to increased sebum production resulting from androgenic changes in serum sexual hormones. Non-inflammatory and inflammatory acne lesions consist of open and/or closed comedones, papules, pustules, and nodules [8]. Triggers for acne can include: Congenital Adrenal Hyperplasia (CAH), Seborrhea-Acne-Hirsutism-Androgenetic Alopecia (SAHA) syndrome, Polycystic Ovary Syndrome (PCO), Hyperandrogenism-Insulin Resistance-Acanthosis Nigricans (HAIR-AN) syndrome, Synovitis-Acne-Pustulosis-Hyperostosis-Osteitis (SAPHO) syndrome, and Pyogenic Arthritis-Pyoderma Gangrenosum-Acne (PAPA) syndrome [1].

Extreme proliferation of *Propionibacterium acnes* (PA) is the main predisposing factor in *Acne vulgaris*. The gram-positive anaerobic bacterium PA settles in skin follicles that are usually bulged and ruptured due to bacterial proliferation, leading to local inflammation followed by the development of pustular acne. Considering the detrimental effects of vitamin D deficiency on the body, it is considered one of the most essential vitamins.

As an antioxidant agent, it has an impact on acne by stimulating superoxide dismutase (SOD) and glutathione peroxidase (GSH-Px), which have been found at lower levels in papulopustular cases of acne [2]. There is limited literature on the transdermal application of vitamin D in the prevention and treatment of acne. The aim of this study was to demonstrate the effectiveness of topical application of vitamin D

on the skin, particularly in cases of strong inflammatory reactions and inflammatory acne.

2. Materials and Methods

Topical (transdermal) application of vitamin D in subjects with inflammatory acne due to vitamin D deficiency lasted for 1 month, after which the research was conducted. Thirty-three subjects participated in this study, including 8 male and 25 female subjects. The regions affected by inflammatory acne were the facial region, thoracic area, and dorsal region. All participants (33) had vitamin D deficiency in their blood, as confirmed by blood test results. Images before and after treatment with vitamin D cream are strictly confidential and, with the consent of one subject, included in this study. The survey was anonymous and strictly confidential, collecting data on the patients' health status and their medical history. Transdermal application therapy with vitamin D did not interfere with the routine documentation of patient treatment and was carried out with their informed consent. The study adhered to the Convention on Human Rights and local laws regarding patient rights, including the Law on Rights, Obligations, and Responsibilities of Patients in the Federation of Bosnia and Herzegovina; the Law on Personal Data Protection in Bosnia and Herzegovina; and the Regulation on Records in the Field of Health in the Federation of Bosnia and Herzegovina.

3. Patents

Vitamin D Cream is a product by brand „Dr. Pasha“ from Sarajevo. The cream has the following details of patent claim:

- Cholecalciferol, Vitamin D₃: Ph Eur,BP,USP;
- CAS-br. 67-97-0;
- Molecular formula: C₂₇H₄₄O (Hill);
- EZ-number 200-673-2;

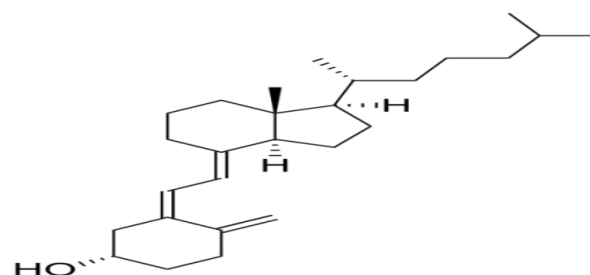


Figure 1. Composition of the general formula of Vitamin D₃

The well-known structure of vitamin D3 is integrated into the cream base, which, due to its composition delivers active substances to the application site. These included: Shea butter, Almond oil and Hydrolyzed oat protein in the form of potassium salts and Xanthan gum, whose composition includes: Agua, Prunus Amygdalus Ducis Oil, Butyrospermum Parkii Butter, Potassium Olivoyl Hydrolyzed Oat Protein, Glycerin, Cetearyl Alcohol, Glyceryl Oleate, Glyceryl Stearate, Dehydroacetic Acid, Benzyl Alcohol, Xanthan Gum, Cholecalciferol, Tocopherol. This cream is intended as dermal support in conditions where there is a need to replenish a deficiency of vitamin D, and it is applied with approximately 1200 IU of vitamin D. It is to be applied to the treated skin twice a day, in the morning and evening, with the aim of delivering an adequate dose of vitamin D to the treated area much faster and more efficiently than would be achieved through oral supplementation.

4. Results

Within *Table 1*, the gender and age structure of participants with a vitamin D deficiency linked to acne is presented. The total number of participants was 33, with 8 participants being male and 25 participants being female. The majority of participants were in the age range of 15-25 years (M=8; F=25), mostly adolescents, while a smaller number of participants were in the age range of 25-35 years (M=1; F=7). However, the smallest number of participants was recorded in the mature population, with only 4 participants (M=1; F=3).

Table 1. Gender and age structure of participants

<i>The age group of participants</i>	<i>The gender group of the participants</i>	
	<i>Male</i>	<i>Female</i>
<i>from 15-25 age</i>	5	16
<i>from 26-35 age</i>	1	7
<i>from 36-45 age</i>	1	3
Total:	8	25

In *Table 2*, the locations of inflammatory acne before treatment with vitamin D cream are presented for the male and female populations. Inflammatory acne locations included the facial region, thoracic area, and dorsal region. Inflammatory acne on the facial region and

thoracic area dominated in the male population (M=3:3; 37.5%), while inflammatory acne on the dorsal region was observed in 2 participants (25%). The female population consisted of 13 participants (52%) with inflammatory acne on the facial region, a smaller number of 10 participants with acne on the thoracic area (40%), and the smallest number, 2 participants, with acne on the dorsal region (8%).

Table 2. Locations of inflammatory acne in male and female participants

<i>The locations of the inflammatory acne</i>	<i>The gender of participants</i>			
	<i>Male</i>		<i>Female</i>	
	<i>N=8</i>	<i>%</i>	<i>N=25</i>	<i>%</i>
<i>Facial region</i>	3	37.5	13	52
<i>Thoracic area</i>	3	37.5	10	40
<i>Dorsal region</i>	2	25	2	8

The state of inflammatory acne after 1-month treatment with vitamin D cream is presented in *Table 3*. The locations of inflammatory acne (facial region, thoracic area, dorsal region) are displayed through the percentages of reduction in inflammatory reactions: 100%, 80%, 50%, 30%, 10%, as well as the category 'no results.' The results indicate the following: Treatment with vitamin D cream for facial region in the male population (N=8) shows a 100% reduction in 2 participants (25%) and an 80% reduction in 1 participant (12.5%). In the female population, 9 participants exhibit a 100% reduction (36%), 2 participants show an 80% reduction (8%), and 1 participant demonstrates a 50% reduction (4%). Regarding the treatment of vitamin D for inflammatory acne on the thoracic area in the male population, 1 participant (12.5%) achieved a 100% reduction, while 2 participants had an 80% reduction (25%). In the female population, different results are observed: 6 participants confirm a 100% reduction (24%), followed by an 80% reduction in 3 participants (12%), and 1 participant with a 50% reduction (8%). The reduction in inflammatory acne on the dorsal region in the male population includes 2 participants with an 80% reduction (25%), while in the female population, there is 1 participant each with an 80% and 50% reduction.

Table 3. Location and reduction of inflammatory acne after one month of applying vitamin D cream

Reduction of inflammatory acne after 1 month of vitamin D application	Gender of participants			
	Male		Female	
	N=8	%	N=25	%
FACIAL REGION				
100% reduction	2	25	9	36
80% reduction	1	12.5	2	8
50% reduction	0	/	1	4
30% reduction	0	/	/	/
10% reduction	0	/	/	/
No improvement observed	0	/	/	/
THORACIC AREA				
100% reduction	1	12.5	6	24
80% reduction	2	25	3	12
50% reduction	0	/	2	8
30% reduction	0	/	/	/
10% reduction	0	/	/	/
No improvement observed	0	/	/	/
DORSAL REGION				
100% reduction	0	/	/	/
80% reduction	2	25	1	4
50% reduction	0	/	1	4
30% reduction	0	/	/	/
10% reduction	0	/	/	/
No improvement observed	0	/	/	/

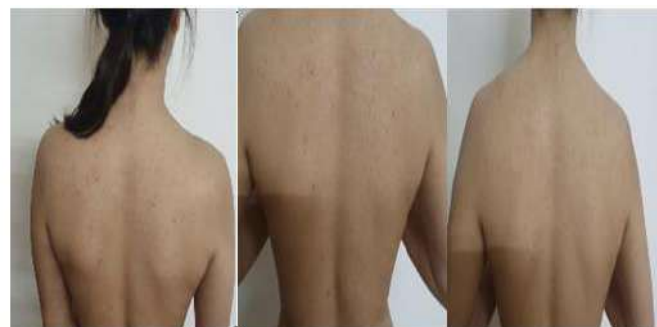

Figure 1. Dorsal region presentation after the application of vitamin D cream (stage of reduction 100%)

5. Discussion

Acne vulgaris (AV) is a multifactorial and complex skin disorder that significantly impacts the quality of life for affected patients. Considering the myriad functions of vitamin D, including the regulation of innate and acquired immunity, as well as the modulation of calcium metabolism and homeostasis, it becomes pertinent to explore its role in this dermatological condition. Numerous etiological factors are implicated in the pathogenesis of acne, with vitamin D deficiency being one such contributory factor.

In the scope of our research, involving 33 participants, 25 were female, while 8 were male. The age range most relevant to the prevalence of acne was identified as 18 to 25 years, corresponding to the adolescent phase. Comparable observations are noted in the literature, aligning with the study [9] which, out of 51 participants, reported 38.1% males and 61.9% females, with an average age between 20-25 years. Similarly, the findings [4] align with our results. In their study of 68 patients, 39.7% were male and 60.3% were female, with the predominant age group being 20 to 25 years. Additionally, according to the Global Burden of Disease (GBD) study, acne affects approximately 85% of young adults aged 12-25 years.

Consistently, acne stands out as one of the most prevalent dermatological conditions in the general population, as evidenced by extensive studies in the United Kingdom, France, and the United States. Androgen production during puberty partially explains the widespread occurrence of acne vulgaris in the adolescent population, irrespective of socio-economic status or nationality. Hormonal factors (imbalance, heightened androgen levels, particularly in women with polycystic ovaries or thyroid disorders),

In *Figure 1*, an illustration of the effect of vitamin D on the dorsal skin region is presented. The results are more than noticeable after the application of vitamin D cream. The cream has completely cleared the region of inflammatory, surface and external acne, and this stage is correlated with *Table 1*. reduction 100%.

dietary choices (high-carbohydrate diets treated with plant hormones), and genetic predisposition contribute to the heightened prevalence of acne during adolescence.

Regions most commonly affected by acne include the facial region, thoracic area, and dorsal region. Research indicates that involvement in the facial region is 58%, thoracic region is 24%, and dorsal region is 40% in males. For females, the involvement in the facial region is 68%, thoracic area is 35.3%, and dorsal region is 54.41% [4]. Our study yielded nearly identical findings: the involvement in the facial and thoracic regions was equal at 37.5%, dorsal region at 25%. Among the female population, the involvement in the facial region was 52%, thoracic region was 40%, and dorsal region was 8%.

The topical application of vitamin D is a relatively understudied topic globally, with limited literature available. However, our research highlights the substantial efficacy of the topical application of vitamin D. After one month of use, it demonstrated remarkable results, significantly reducing or completely eliminating the presence of inflammatory acne in areas such as the face, chest, and dorsal region. Such research could contribute to and advance the exploration of the benefits of transdermal application of vitamin D, shedding light on its positive impact on skin health.

6. References

1. Abdelaziz, W. M., Farahat, T. M., Shaheen, H. M., Gaber, M. A. (2021). Effect of vitamin D supplementation on patients with acne vulgaris: An intervention study. *The Egyptian Family Medicine Journal*, 5(1), 177-187.
2. Abdel-Wahab, H. M., Ali, A. K., Ragaie, M. H. (2022). Calcipotriol: A novel tool in treatment of acne vulgaris. *Dermatologic Therapy*, 35(9), e15690.
3. Ahmed Mohamed, A., Salah Ahmed, E. M., Abdel-Aziz, R. T., Eldeeb Abdallah, H. H., El-Hanafi, H., Hussein, G., El Borolossy, R. (2021). The impact of active vitamin D administration on the clinical outcomes of acne vulgaris. *Journal of Dermatological Treatment*, 32(7), 756-761.
4. Alhetheli, G., Elneam, A. I. A., Alsenaid, A., & Al-Dhubaibi, M. (2020). Vitamin D levels in patients with and without acne and its relation to acne severity: a case-control study. *Clinical, Cosmetic and Investigational dermatology*, 759-765.
5. Amrein, K., Scherkl, M., Hoffmann, M., Neuwersch-Sommeregger, S., Köstenberger, M., Tmava Berisha, A., Malle, O. (2020). Vitamin D deficiency 2.0: an update on the current status worldwide. *European Journal of Clinical Nutrition*, 74(11), 1498-1513.
6. Cashman, K. D. (2020). Vitamin D deficiency: defining, prevalence, causes, and strategies of addressing. *Calcified Tissue International*, 106(1), 14-29.
7. Leung, A. K., Barankin, B., Lam, J. M., Leong, K. F., Hon, K. L. (2021). Dermatology: how to manage acne vulgaris. *Drugs in Context*, 10.
8. Saptarini, D., Witjaksono, F., Sitohang, I. B. S. (2020). Correlation study of acne vulgaris and serum vitamin D levels in adolescents. *International Journal of Applied Pharmaceutics*, 19-21.
9. Shaker, O. G., Abd el-Raheem, T. A., & Yasen, S. M. (2022). Analyses of serum 25-hydroxyvitamin D levels and single nucleotide polymorphisms in the vitamin D receptor gene for acne vulgaris: a case-control study. *Egyptian Journal of Dermatology and Venerology*, 42(1), 60-67