

HYPERVITAMINOSIS D

Report of 9 Cases

R. W. SCHNEIDER, M.D., and H. KAMMER, M.D.

Section on Endocrinology

HYPERVITAMINOSIS D may result from the prolonged use of vitamin D₂ and related sterols. The clinical manifestations of this condition include polydipsia, polyuria, muscular weakness, and headache, while less frequently drowsiness, nausea, vomiting, and diarrhea may appear. These symptoms are almost invariably accompanied by hypercalcemia and, at times, by widespread metastatic calcification in soft tissues. Since the kidney is particularly susceptible to metastatic calcification, serious impairment of renal function usually attends the intoxication and, if unrecognized, may prove fatal. It has been clearly demonstrated that all members of the vitamin D complex are capable of producing injurious effects.¹

Case Reports

Case 1. A white man, aged 27, was first seen on October 29, 1946, because of severe rheumatoid arthritis of two years' duration. He had been taking vitamin D in capsules, but the exact form of drug, amount, and duration of treatment are not recorded. The patient had had an attack of "flu" five months previously, and since that time he had noted recurring headaches, muscle weakness, bouts of conjunctivitis, and increasing frequency and nocturia. Neither hematuria nor urethral discharge had ever been noticed.

On physical examination the weight was 145 pounds and the blood pressure 160 systolic, 90 diastolic. There was mild injection of the conjunctivae and a grade II constriction and sclerosis of the retinal vessels. No hemorrhages or exudate were noted. There was fusiform swelling of the first two fingers of the right hand, and the right knee was swollen. Anemia, proteinuria, azotemia, and impaired renal function were demonstrated. The blood urea measured 84 mg. per cent, and the urea clearance test gave values of 32 per cent and 36 per cent in the first and second hours, respectively. The urine had a specific gravity of 1.010 and grade II albumin. Blood studies revealed 3,900,000 red cells, hemoglobin 71 per cent, and 10,650 white cells. Blood calcium measured 14.5 mg. per cent, blood phosphorus 3.7 mg. per cent, and blood chloride 561 mg. per cent. Plasma proteins, using the Tiselius method, were normal. An intravenous urogram revealed poor renal excretion of diodrast. There was moderate calcification of the pelvic vessels (fig. 1), an interesting finding in a young person.

A diagnosis was made of rheumatoid arthritis with renal insufficiency due to vitamin D intoxication.

Six months following the withdrawal of vitamin D the patient had improved, and nocturia and polyuria had disappeared. An Addis test gave normal findings; blood urea was 45 mg. per cent, and urea clearance values were 62 per cent and 56 per cent in the first and second hours, respectively. There was no significant change in the calcification of the pelvic vessels.

Case 2. A white woman, aged 55, was admitted to the Cleveland Clinic Hospital on November 16, 1946, with an acute exacerbation of rheumatoid arthritis. She had had rheumatoid arthritis for ten years, and the shoulders, elbows, wrists, fingers, and knees were typically deformed. She had noted the onset of nocturia about one year prior to admission. This had progressed until she was urinating six or seven times each night. Fluids had been limited in an attempt to decrease this symptom. A long history of vitamin D intake was obtained. Six years previously she had taken 100 capsules (50,000 I.U. each) in divided doses, and three

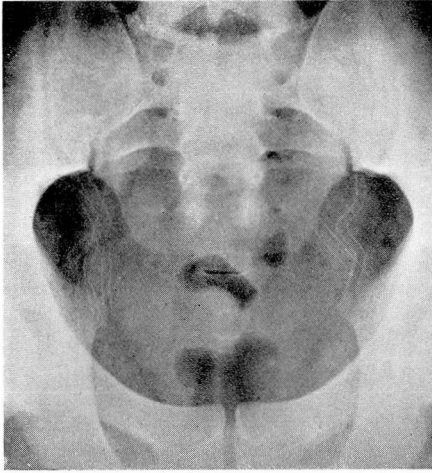


FIG. 1. Case 1. Calcification of pelvic vessels in a 27-year-old man.

years later had resumed the drug, taking 300,000 units daily for two months. She was forced to discontinue the drug at that time because of nausea and vomiting. For the year and a half preceding admission to the hospital she had taken 150,000 units of vitamin D per day.

On examination the patient appeared chronically ill. The blood pressure was 120 systolic, 70 diastolic. There was grade II sclerosis of retinal arteries. A soft apical systolic murmur was present. The liver was palpable 3 fingers' breadth below the right costal margin, and the spleen was barely palpable. The joints in general were warm, and fusiform deformities were present. The proximal interphalangeal joints of the fingers were most involved.

Blood studies revealed 2,540,000 red cells, hemoglobin 7.7 Gm. (50 per cent), 9400 white cells, sedimentation rate 1.3 mm. per minute (normal up to 0.45 mm. per minute). The urine had a specific gravity of 1.011 and contained a trace of albumin. The Sulkowitch test* for urinary calcium was slightly increased. The blood urea measured 123 mg. per cent with urea clearance values of 11 per cent and 13 per cent in the first and second hours, respectively. Blood calcium levels were 10.7 mg. and 12.1 mg. per cent on two occasions, and blood phosphorus was 6.1 mg. per cent. Alkaline phosphatase was 3.7 Bodansky units. Values for total proteins were 7.5 Gm. per cent, and fractionation by the Tiselius electrophoretic method revealed a slight increase in the beta globulin fraction.

Roentgenologic studies revealed extensive calcification in the soft tissues about the shoulders (fig. 2) as well as in the aorta and the vessels of the thighs and pelvis. Calcification was present in the lower calyx of the left kidney. A large, sharply demarcated, calcific deposit was present just above the right greater trochanter (fig. 3). An intravenous urogram showed decreased diodrast clearance.

Subsequent studies of renal function following the withdrawal of vitamin D have not been possible.

*The Sulkowitch test is performed by the addition of an equal volume of reagent to urine. The reagent consists of:

Oxalic acid	2.5 Gm.
Ammonium oxalate	2.5 Gm.
Glacial acetic acid	5.0 Gm.
Distilled water to make	150.0 Gm.

The degree of calciuria is estimated by the intensity and speed of formation of a fine white, flocculent precipitate.

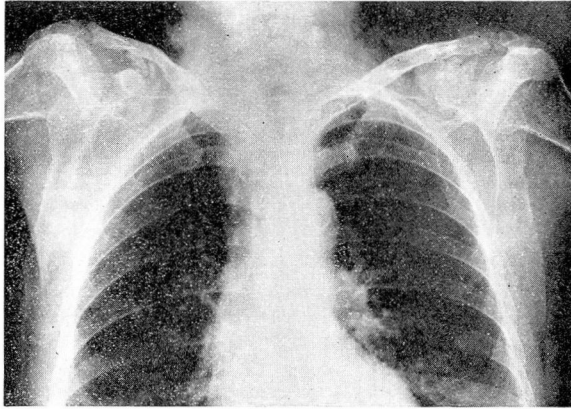


FIG. 2. Case 2. Roentgenogram showing metastatic calcification in region of clavicles.

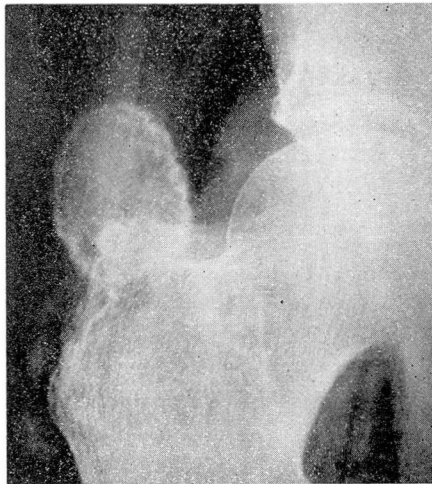


FIG. 3. Roentgenogram showing metastatic calcification in region of greater trochanter of femur.

Case 3. A white woman, aged 57, was first admitted October 25, 1946, complaining of nervousness and weakness of long duration. She had had unexplained stiffness and pain in her fingers and knees, for which Ertron, 200,000 to 300,000 units daily, had been prescribed. She had taken the drug intermittently for three years. In the two years preceding admission she had had recurring attacks of chills, fever, and dysuria. She had developed anemia in the previous six months, for which liver injections had been given. A hacking cough, a rather persistent conjunctivitis, muscular weakness, drowsiness, polyuria, and headache had appeared.

On examination the blood pressure was 150 systolic, 80 diastolic. The patient appeared chronically ill. A severe bilateral conjunctivitis was present. There was calcification of both tympanic membranes and hearing was poor. There was a grade II systolic murmur at the apex and diffuse tenderness in both costovertebral angles.

Laboratory studies disclosed moderate proteinuria, marked suppression of renal function, severe anemia, and hypercalcemia. Total blood proteins were 6.6 Gm. per cent, blood

HYPERVITAMINOSIS D

calcium 14.0 mg. per cent, and phosphorus 4.0 mg. per cent. Hemoglobin measured 6 Gm. per cent (Haden-Hauser). Blood urea measured 84 mg. per cent, and urea clearance gave values of 13 per cent and 14 per cent in the first and second hours.

Vitamin D was discontinued and four weeks later urea measured 78 mg. per cent, and urea clearance test was 26 per cent and 30 per cent in the first and second hours. Blood calcium determinations were 13.5 mg., 13.8 mg., and 15.0 mg. per cent and blood phosphorus 4.4 mg., 5.2 mg., and 3.8 mg. per cent.

Roentgenologic studies disclosed areas of calcification in the costal cartilages and in the soft tissue overlying the greater trochanter of the left femur. Calcification was also present in the midline of the skull and was considered to be in the falx.

Six months later the patient was reported to be in good general health. Blood calcium and phosphorus levels were normal. Total blood proteins were 6.4 Gm. per cent, blood urea 23 mg. per cent, red blood count 2,700,000, and hemoglobin 58 per cent. Moderate proteinuria persisted. Roentgenologic studies showed calcification of the posterior tibial arteries and shadows suggesting early deposition of calcium in scattered areas.

Case 4. A woman, aged 54, was admitted in September, 1946, complaining of arthritis of the hands and feet of twenty years' duration. Headache, generalized muscular weakness, polydipsia, polyuria, and puffiness about the eyes had been noted, and an intravenous urogram, done elsewhere, had failed to demonstrate the kidneys. Hypertension and blurring of vision had been attributed to "kidney disease." She had taken vitamin D, 150,000 units daily, during June and July, 1946.

On examination the patient appeared chronically ill. Blood pressure was 160 systolic, 80 diastolic. Eye grounds showed grade II sclerosis of arteries, no hemorrhages or exudates. There was pain and tenderness in the knees and interphalangeal joints of the fingers. Heberden's nodes were present.

An Addis test revealed the urine to have a maximum specific gravity of 1.014; .08 Gm. of protein were excreted in twenty-four hours. Blood urea measured 45 mg. per cent, and urea clearance values were 25 per cent the first hour and 24 per cent the second hour. Red blood count showed 3,200,000 cells with 9 Gm. hemoglobin. Gastric analysis showed 41 per cent free acid. An intravenous urogram demonstrated poor renal function. Blood calcium and phosphorus levels obtained three months later gave values of 12.3 mg. and 3.0 mg. per cent, respectively. The blood urea at this time was 34 mg. per cent.

Case 5. A white woman, aged 52, was examined on May 13, 1947, because of rheumatoid arthritis of four and one-half years' duration. She had taken 4 capsules of Ertron daily from February to November, 1946, when she discontinued the drug because of nausea and vomiting. When these symptoms subsided she resumed the drug, taking 4 capsules daily, plus a weekly injection of Ertron for the next four months. She had noted generalized muscular weakness.

On physical examination the only positive finding was a grade III rheumatoid arthritis. Urinalysis disclosed a specific gravity of 1.008-10, and no sugar, albumin, or cells. Blood urea was 36 mg. per cent, and urea clearance values were 40 per cent the first hour and 42 per cent the second hour. Blood calcium was 11.5 mg. per cent, and phosphorus was 3.2 mg. per cent. The blood proteins were 7.6. The suppressed renal function and elevated blood calcium were attributed to vitamin D intoxication.

One month after withdrawal of the drug, the blood calcium was 10.5 mg. per cent, and phosphorus was 3.0 mg. per cent. Kidney function tests were not carried out, but there was no clinical evidence of renal failure, and the patient felt improved.

Case 6. A white woman, aged 34, was admitted on January 9, 1947, complaining of nausea and vomiting of all food, including gelatin and gruels. She had had a similar attack of nausea with vomiting one month before which lasted five days. For the previous one and one-half years she had had recurring bilateral frontal headaches. Polyuria, nocturia, muscle weakness, and drowsiness had appeared. There was no history of renal disease or infection; however, the patient had been taking daily doses of vitamin D for six weeks prior to admission to the hospital. Neither the exact amount nor the form of vitamin D taken was revealed.

Physical examination gave normal findings. Upon urinalysis, the Addis test demonstrated a specific gravity of 1.019 and normal amounts of casts and cells. Albumin was .288

Gm. per liter, sugar .219 Gm. per twenty-four hours. The Sulkowitch test showed increase in urine calcium. The white blood count was 6950, hemoglobin 9.5 Gm. (61 per cent), blood calcium 15.2 mg., phosphorus 2.4 mg., and urea 60 mg. Urea clearance was 30 per cent of normal. Wassermann and Kahn reactions were negative.

An intravenous urogram revealed poorly functioning kidneys, and a retrograde pyelogram gave normal findings. Cystoscopic examination was negative.

Vitamin D was discontinued, and there was a gradual return to almost normal kidney function eight months later. The only medication given was iron for the anemia. On January 30, 1947, the blood urea was 33 mg. per cent with urea clearance values of 47 per cent and 40 per cent in the first and second hours. Blood calcium was 10.5 mg. per cent, phosphorus 3.2 mg. per cent. On February 22, 1947, the blood urea was 24 mg. per cent with urea clearance values of 53 per cent and 58 per cent in the first and second hours. On August 9, 1947, blood urea measured 30 mg. per cent with urea clearance determinations of 82 per cent and 74 per cent in one and two hours, respectively.

Case 7. A white man, aged 60, was first examined on December 18, 1946, complaining of extreme thirst of five weeks' duration. He thought he had been drinking a gallon of water per day, and frequency in urination was present. Headache, nausea, vomiting, and blurring of vision had appeared. For the preceding ten days he had noted swelling of the legs, drowsiness, and generalized muscular weakness. Weight loss had been gradual but steady. He had been taking Ertron, 1 capsule three times daily, for the preceding ten months for a rather extensive hypertrophic arthritis.

On examination the blood pressure was 160 systolic, 72 diastolic. There was evidence of hypertrophic arthritis in the knees. There was grade I pitting edema over the sacrum and ankles. Peripheral arteries were hardened. Neurologic examination disclosed a slight nystagmus on lateral gaze, diminished vibratory sense in the lower part of his legs, and generalized motor weakness.

Laboratory studies revealed a blood calcium of 15.5 mg. per cent, and blood urea was 78 mg. per cent. Urinalysis was normal except for a specific gravity of 1010. Blood studies disclosed 4,400,000 red cells, hemoglobin 11.5 Gm. (74 per cent), and 9300 white cells. The basal metabolic rate was minus 13 per cent. Wassermann and Kahn reactions were negative. Spinal fluid gave normal findings.

Vitamin D therapy was discontinued and three weeks later the blood calcium was 12.0 mg. per cent, phosphorus 2.6 mg. per cent, and urea 45 mg. per cent. Ten months after his initial visit the patient felt completely well. Laboratory studies at this time revealed a blood urea of 30 mg. per cent with urea clearance values of 72 per cent in the first hour and 75 per cent in the second hour. Blood calcium and phosphorus levels were normal, being 10.8 mg. and 3.4 mg. per cent respectively.

Case 8. A white man, aged 53, was seen on March 31, 1947, complaining of low back pain of four months' duration. During this time he had been taking vitamin D, 350,000 to 500,000 units daily, until one week prior to admission. Two weeks before admission he had experienced a gastrointestinal upset, with nausea, vomiting, and constipation. Headache, polyuria, nocturia, muscular weakness, and nervousness had been constant.

Physical examination was negative except for poor posture and diffuse tenderness over the lumbar spine.

On laboratory examination the blood urea measured 54 mg. per cent, blood calcium 15.4 mg. per cent, phosphorus 3.5 mg. per cent, and urea clearance 26 per cent the first hour and 30 per cent the second hour. The urine at this time had a fixed specific gravity of 1.008. Roentgenologic studies revealed osteoarthritis of the lumbar spine.

One month after withdrawal of vitamin D, gastrointestinal symptoms disappeared. There was evidence of improving renal function, in that the blood urea was reduced to 39 mg. per cent, blood calcium was 11.0 mg. per cent, and phosphorus was 2.9 mg. per cent.

Three months later the patient was greatly improved and the nocturia had almost disappeared. Blood urea was 33 mg. per cent with clearance values of 112 per cent the first hour and 82 per cent the second hour. Blood calcium was 10.1 mg., phosphorus 2.9 mg.

Six months later an Addis count on the urine revealed a specific gravity of 1.022, protein 5.56 Gm. excreted in twenty-four hours, casts 200,000, red blood count 7,250,000, white

blood count 100,000. This was interpreted as evidence of inflammatory disease of the kidneys resulting from previous vitamin D intoxication.

Case 9. A white woman, aged 49, was admitted on October 14, 1944, because of nausea and vomiting of three weeks' duration. During this time she had suffered from recurrent headaches of excruciating nature. She had also noted recent onset of nocturia, occurring twice nightly. She was unable to sit up in bed because of muscle weakness, and drowsiness was excessive. She had been taking 300,000 units of vitamin D daily for several months prior to admission.

On examination the blood pressure was 170 systolic, 110 diastolic. The eye grounds were normal. Heart and lungs were normal. There was no peripheral edema. The urine had a specific gravity ranging from 1.005 to 1.011, and there was a trace of protein in the urine.

Blood urea was 45 mg. per cent, and the urea clearance values were 36 per cent the first hour and 31 per cent the second hour. Plasma protein measured 5.4 Gm. per cent. Blood calcium was 11.9 mg. per cent and 11.3 mg. per cent, and the blood phosphorus was 2.8 mg. and 3.3 mg. per cent. Mild anemia was manifest, with hemoglobin of 68 per cent. Alkaline phosphatase measured 2.4 Bodansky units. An intravenous urogram showed poor clearance of diodrast. Roentgenologic examination disclosed calcification of the choroid plexus in the skull and generalized osteoporosis of the long bones.

A follow-up study after six months showed improvement in renal function, with a blood urea of 27 mg. per cent and a urea clearance of 56 per cent and 58 per cent in the first and second hours. The patient felt much better at this time.

Discussion

The calcium in the blood is contained entirely within the plasma. Quantitative determinations are best obtained from serum which normally contains from 9 to 11 mg. per 100 cc. This total serum calcium exists in two forms, an unbound, or ionizable fraction, and a protein-bound, or nonionizable fraction,

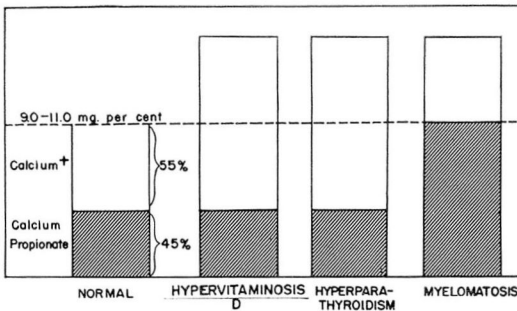


FIG. 4. Relation of calcium fractions in three diseases characterized by hypercalcemia.

attached principally to serum albumin. Under normal conditions these two forms are approximately equal in amount.

Abnormally high or low levels of serum calcium may result from an increase or decrease in either or both of these fractions. Although hypercalcemia is common in hyperparathyroidism, hypervitaminosis D, and myelomatosis, differences in the symptoms in these conditions may be partially explained in the alteration of serum calcium fractions (fig. 4).

The most prominent symptoms of hypervitaminosis D consist of polydipsia, polyuria, muscular weakness, and headache, and, less frequently, drowsiness, nausea, vomiting, and diarrhea. In hyperparathyroidism similar symptoms are

frequently manifest. In both of these conditions hypercalcemia is attributable to a rise in the ionizable calcium fraction, although the responsible mechanisms appear to be dissimilar. Total blood proteins are not increased in either. Furthermore, when hypercalcemia is corrected by either the withdrawal of the drug or the removal of a parathyroid adenoma, these symptoms disappear. Further, in myelomatosis, hypercalcemia, when present, is apparently due to an increase in protein-bound calcium and not to diffusible calcium. Polyuria, polydipsia, muscular weakness, and drowsiness are not outstanding symptoms in this condition. A relation between an increase in ionic calcium in the blood and common symptoms is strongly suggested.

However, toxic symptoms may appear at times in persons taking vitamin D in whom elevated blood calcium levels cannot be demonstrated.³ It has been suggested, therefore, that vitamin D may be a primary irritant to tissue cells in some individuals and may be a factor more responsible for production of toxic manifestations than commonly considered.

The principal harm attending excessive administration of vitamin D is derived from metastatic calcification. If the drug is continued indefinitely irreversible damage to soft tissues, particularly the kidney, may ensue. Individual susceptibility to the drug is quite variable. Intoxication has been reported to result from as little as 1000 international units per kilogram per day.³ On the other hand, it has been tolerated by others in doses up to 35,000 international units per kilogram per day.⁴ In the patients studied by Reed *et al.*³ symptoms of vitamin D toxicity occurred most frequently in those who also had gastrointestinal dysfunction such as diarrhea or constipation and, according to them, a number of factors influenced the toxicity of the vitamin. Included were the dosage per unit of body weight, the diet, purity of the vitamin, and the vehicle in which it is administered. The toxic property of the drug itself⁵ depends in part upon the methods used to produce the drug. Frequent toxic effects which followed the use of ultraviolet-irradiated ergosterol were attributed to the large toxisterol content. The ergosterol which is activated by the electrical method of Whittier is considered to be somewhat less toxic. It would appear, however, that no form of vitamin D should be used indiscriminately.

The chief mode of action of vitamin D is to increase the absorption of calcium from the gastrointestinal tract. A consequent rise in diffusible calcium within the blood can thus be readily transferred to tissue cells. Widespread deposits of calcium presumably mobilized in this manner have been found in the various soft tissues. Experimental animals killed by sufficiently large doses of irradiated ergosterol repeatedly demonstrated diffuse metastatic calcification involving the arteriovascular system in the kidneys. Steck and his co-workers,⁴ using dogs as experimental animals, fed them 20,000 to 1,000,000 international units per kilogram per day. Abnormally high levels of blood calcium appeared, and all died in coma when the drug was continued. Autopsy findings revealed the kidneys to be the most vulnerable organ. These workers hypothesized that the sequence of events included an initial injury to the tissue cells by the vitamin, followed by a deposition of calcium within the injured cells.

A case reported by Bauer and Freyberg⁵ gives a striking example of metastatic calcification in the advanced stage of vitamin D intoxication. The arterio-

vascular system, the myocardium, lungs, and kidneys were sites of intense deposition of calcium salts. The kidneys were the most seriously involved, the renal arterioles being "primarily affected." The tubular and glomerular cells were less involved. The lumen of the tubules also contained calcium. Arterial calcification seemed to be limited to the media, the intima being spared in most instances.

Calcific deposition seems to be favored in acid-secreting cells with an alkaline reaction, such as in the kidneys, the lungs, and in the lining of the fundus of the stomach. Gough⁶ and associates showed that the pH of excreted urine in some way altered the renal calcification of rats intoxicated with calciferol. Animals fed an acid ash diet developed different renal lesions than did those maintained on an alkaline ash diet.

Caution should be employed in the prolonged use of vitamin D in all persons because the individual susceptibility to the drug varies widely and because its optimum toxic effects may not be manifest for some months. Renal insufficiency should be regarded as a contraindication to the use of vitamin D. Blood calcium determinations should be made at repeated intervals on all patients taking vitamin D, since the cumulative action of the drug may not be detectable for many months. Only in this way will the early manifestations of hypervitaminosis D be recognized and the serious undesirable side-effects of metastatic calcification be prevented. Once induced, hypercalcemia, renal insufficiency, and metastatic calcification in other soft tissues may persist for many months after the drug is discontinued.

Summary

Roentgenologic evidence of metastatic calcification outside the kidneys was present in 2 of 9 cases of hypervitaminosis D. All 9 showed significant impairment of kidney function. Toxic symptoms included headache, nausea and vomiting, muscular weakness, drowsiness, polydipsia, and polyuria.

Discontinuance of vitamin D resulted in the disappearance of toxic symptoms in all cases. Kidney function improved significantly in the 7 cases in which follow-up studies were obtained.

In the 2 cases with metastatic calcification there was no evidence of roentgenologic improvement during the period of observation.

References

1. Freyberg, R. H.: Treatment of arthritis with vitamins and endocrine preparations; emphasis on their limited value. *J.A.M.A.* **119**:1165-1171 (Aug. 8) 1942.
2. Macrae, D. E.: Calciferol treatment of lupus vulgaris. *Brit. J. Dermat.* **59**:333-338 (Oct.) 1947.
3. Reed, C. I., Struck, H. C., and Steck, I. E.: Vitamin D: Chemistry, Physiology, Pharmacology, Pathology, Experimental and Clinical Investigations. (Chicago: University of Chicago Press, 1939).
4. Steck, I. E., Deutsch, H., Reed, C. I., and Struck, H. C.: Further studies on intoxication with vitamin D. *Ann. Int. Med.* **10**:951-964 (Jan.) 1937.
5. Bauer, J. M., and Freyberg, R. H.: Vitamin D intoxication with metastatic calcification. *J.A.M.A.* **130**:1208-1215 (April 27) 1946.
6. Gough, J., Duguid, J. B., and Davis, D. R.: Renal lesions in hypervitaminosis D.: observations on urinary calcium and phosphorus excretion. *Brit. J. Exper. Path.* **14**:137-145 (June) 1933.